


## CASO 1

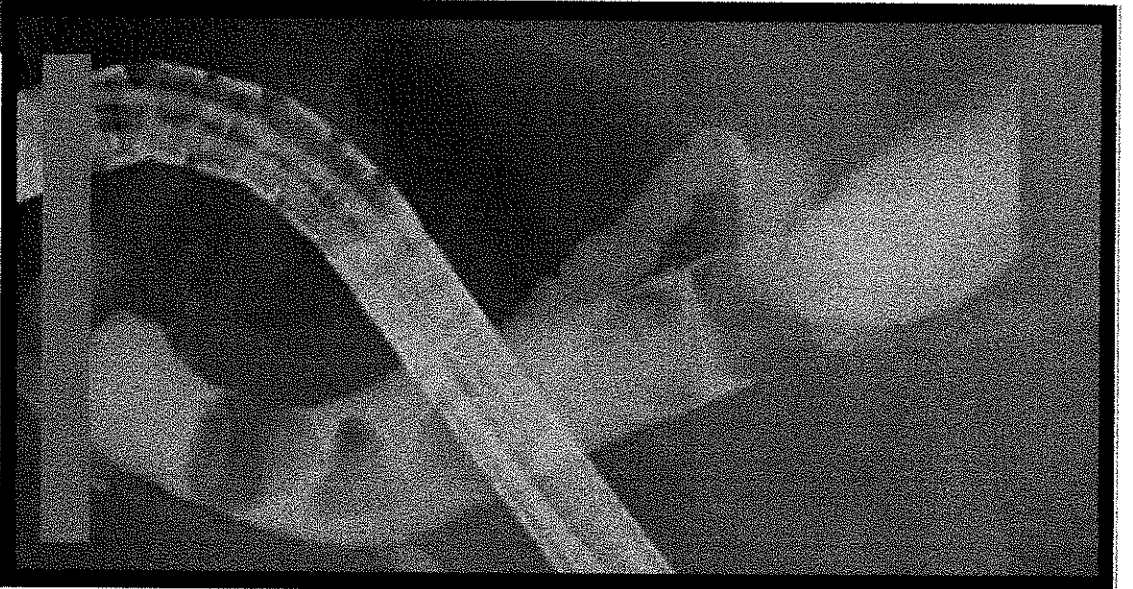
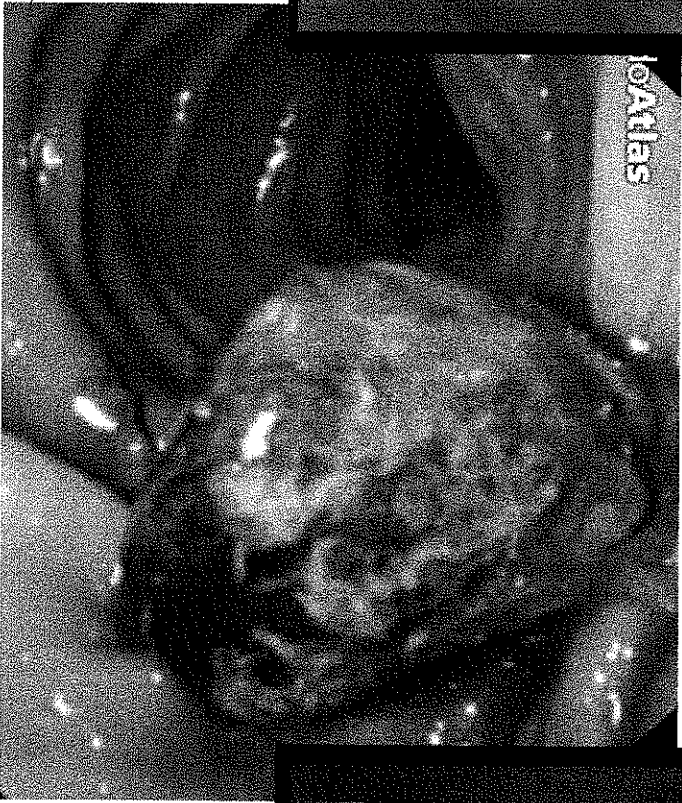57 AA, F.

Ricoverato per ittero ingravescente da 15 giorni e feci ipocoliche con urine ipercromiche da 4 giorni. Al momento del ricovero Bil. 18,1 mg/dL di cui diretta 12.2 mg/dL. PCR 1.64 mg/dl.

Comorbidità: ipertensione arteriosa.

A large, stylized handwritten signature in black ink, followed by several horizontal scribbles and a small mark resembling a checkmark or a cross.

ALESGATO N. 1/B



Handwritten scribbles and a large looped mark, possibly initials or a signature.

Handwritten scribbles, possibly initials or a signature.